



Iliac-mesenteric-caval shunting in patients under two years of age. Case reports and review of the literature

Noe Villanueva-López¹
Karla Alejandra Santos-Jasso²
María Alicia Martínez-Pérez³
Francisco Antonio Medina-Vega⁴

¹ Fourth year resident, Pediatric Surgery, Instituto Nacional de Pediatría.

² Pediatric Surgeon. Staff Physician, Colorectal Surgery. Instituto Nacional de Pediatría.

³ Neonatologist. Hospital Ángeles del Pedregal.

⁴ Head of Pediatric Surgery Service, Instituto Nacional de Pediatría. Manager of Hepatobiliopancreatic Surgery Clinic.

ABSTRACT

Introduction: in treating portal hypertension in pediatric patients, some form of portosystemic shunting is indicated, a surgical procedure rarely used in patients under two years of age due to the infrequency of the condition in that age group and the increase in complications.¹

Objective: discuss the experience and results of this procedure in patients under two years of age attended at the Hepatobiliopancreatic Surgery clinic of the General Surgery Service at Instituto Nacional de Pediatría.

Discussion: the causes of portal hypertension at pediatric age are varied. Of extrahepatic manifestations, the most common is portal cavernomatous degeneration. Children under two years of age with portal hypertension have severe symptoms such as recurrent or anemia-causing digestive bleeding; others have signs of hypersplenism. In many cases medical treatment has no usefulness and surgical intervention, such as portosystemic shunting, is required to reduce the size of varices and prevent life-threatening bleeding.

Conclusion: iliac-mesenteric-caval shunting in patients under two years of age is a feasible alternative which improves the patient's clinical status, reducing the risk of bleeding; however, long-term studies are needed to observe such patients' evolution.

Key words: iliac-mesenteric-caval shunting, portal hypertension.

Received: February, 2012

Accepted: November, 2013

Correspondence

Dr. Francisco Antonio Medina Vega
Servicio de Cirugía Pediátrica
Instituto Nacional de Pediatría
Avenida Imán # 1, piso 9
Col. Insurgentes Cuicuilco
CP. 04530. México, D.F.
amedinavega@yahoo.com

This article must be quoted

Villanueva-López N, Santos-Jasso KA, Martínez-Pérez MA, Medina-Vega FA. Derivación ilíaca-mesentérico-cava en pacientes menores de dos años de edad. Informe de casos y revisión de la literatura. Acta Pediat Mex 2014;35:130-136.

Today we know that portal hypertension is not a purely mechanical phenomenon. In this condition hemodynamic alterations in the hepatic and systemic circulatory systems coexist and, in combination with mechanical factors, contribute to the appearance of portal hypertension.

In the hepatic circulation, hemodynamic alterations are characterized by vasoconstriction and anomalous response to vasodilation, whereas in the systemic circulation, especially in the splanchnic bed, the blood vessels are congested and have increased flow. Therefore, an increase in hepatic resistances due to increased portal vein flow, mediated through splanchnic dilation, contributes to the development of portal hypertension; the consequence of increased flow and transmural pressure through the collateral vessels, from a hypertense portal vasculature, toward the systemic venous circulation with lower pressure, is the cause of many complications of portal hypertension, such as bleeding of esophageal varices.²

The causes of portal hypertension may be of three types:

1. Prehepatic causes. Alterations in the arrival of the portal hepatic flow: extrahepatic portal hypertension and cavernomatous degeneration of the portal vein.
2. Hepatic causes. Increase in hepatic vascular resistance caused by cirrhosis due to biliary atresia, hepatic fibrosis.
3. Posthepatic causes. Alterations in discharge of portal hepatic flow: most commonly hepatic vein obstruction or Budd-Chiari syndrome.³

Portal hypertension is defined as a gradient of hepatic pressure above 6 mmHg, as intrasplenic pressure above 15 mmHg, or last as direct

portal vein pressure above 21 mmHg (30 cm of water).⁴

In recent years multiple forms of treatment have been proposed to control the bleeding due to rupture of esophageal varices these patients often experience.⁵ To date there is no ideal therapeutic method which, as treatment of first intention, solves the problem in both children and adults.^{6,7}

Santi and Marion in 1953 and 1954^{8,9} and Clatworthy in 1955⁹ proposed mesenteric-caval shunting, and Clatworthy and Boles, in 1959,¹⁰ described proximal splenorenal shunting for treating portal hypertension in children.

At Instituto Nacional de Pediatría, the therapeutic methods of choice for patients with prehepatic portal hypertension are mesenteric-iliac and proximal splenorenal shunting.

Portosystemic shunting is a surgery rarely used in patients under two years of age because patients with portal hypertension with anemia-causing or life threatening recurrent digestive bleeding are usually older. Other patients, usually over four years of age, develop hypersplenism; however, it occurs with increasing frequency in younger patients.

Distal splenorenal (Warren) shunting is one of the procedures of choice in patients with portal hypertension due to its selectiveness; however, in patients under two years of age the gage of splenic blood vessels makes it technically difficult to perform, in addition to significantly increasing the chance of thrombosis, for which reason iliac-mesenteric-caval shunting is the most commonly used type.

In the domestic and international literature there are isolated reports of patients under two years of age with portal hypertension who have undergone some form of surgical bypass.

One of the first articles to provide information on this type of procedures was published by Bismuth et al., who describe the first 90 cases in which some form of bypass was performed, among them patients from 18 months to 15 years of age. In 19 of the 90 patients, mesocaval shunting was performed; five of them were under two years of age, but the article does not specify what type of shunting was performed. Of all the patients operated on, only 5% presented thrombosis.¹

One of the most important projects undertaken in Mexico was conducted by Vargas Gomez et al., who conducted a retrospective study of 34 patients with prehepatic portal hypertension between 7 months and 14 years of age, who underwent iliac-mesenteric and proximal splenorenal shunting between 1980 and 1991. They observed a large difference between iliac-mesenteric shunting, which was performed with a difference of three years before the splenorenal shunting, more conspicuous in patients under eight years of age: in 14 of their 15 patients who underwent surgery before that age iliac-mesenteric shunting was performed. The authors reported two cases of patients under 2 years.¹¹

Alvarez et al. published a study of 108 patients with portal hypertension: 76 underwent portosystemic surgery; in 32 they used splenorenal (Warren) shunting as the initial procedure and in another 32 patients they used mesocaval shunting; in the others they used other types of shunting. Only four patients of the 76 were under two years of age; two developed thrombosis. The indication for surgery was the same as for our patients: digestive tract bleeding. As in our patients, the outcome was acceptable, with improved quality of life.¹²

A systematic review was conducted through PubMed, with search criteria including cases

under two years of age with this type of shunting. A large majority of studies included series of patients over two years of age, as well as other types of portosystemic shunting different from our cases.

The objective is to discuss our experience and the results of this procedure in patients under two years of age.

CASE 1

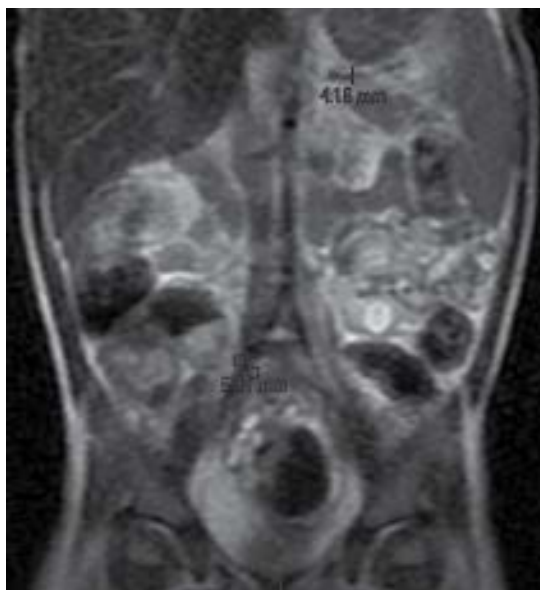Girl age 1 year 9 months with history of meconium aspiration; at birth she presented bleeding from the digestive tract and anemia. At 1 year 3 months of age, presenting similar manifestations for one week, she required blood products and hospitalization due to hematemesis and hemodynamic decompensation (Table 1). During her hospitalization she underwent an endoscopy which showed G3 esophageal and fundal varices, as well as a congestive gastroduodenopathy (Table 2). At 1 year 6 months she had idiopathic thrombocytopenic purpura and bleeding from the upper digestive tract. She was given steroid treatment. She was hospitalized at age 1 year 9 months. She underwent magnetic angioresonance, which showed a cavernomatous degeneration of the portal vein with multiple splenogastric, splenorenal, and splenosystemic collaterals (Figure 1), a splenomegaly measuring 11.5 × 4.4 cm associated with hypersplenism,

Table 1. Comparison of cases with regard to onset of symptoms

	Case 1	Case 2
Manifestation	1 year 9 months	1 year 6 months
Start of digestive tract bleeding	1 year 2 months	1 year 1 month
Hospitalizations prior to surgery	1 time	4 times
Required management	Blood products	Blood products

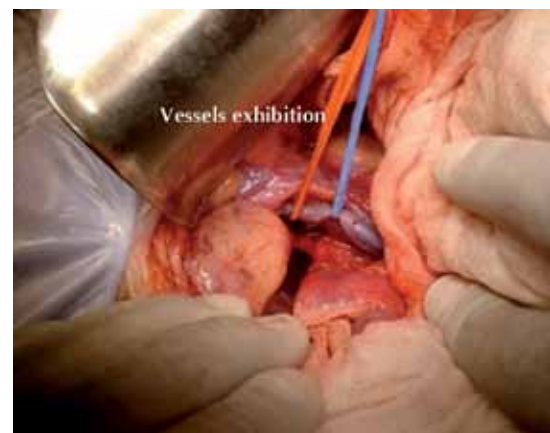Table 2. Preoperative studies

Initial studies	Case 1	Case 2
Ultrasound	Splenomegaly, 11.5 × 4.4 cm	Splenomegaly, 10.6 × 4.5 cm
Magnetic resonance angiography	Multiple splenogastric, splenorenal, and splenosystemic collaterals	Multiple splenogastric, splenorenal, and splenosystemic collaterals
Endoscopy	Grade 3 varices (3, 6 and 7 hours)	Grade 3 and 4 varices (6 and 9 hours, respectively)
Platelet count	75,000/mm ³	59,000/mm ³

**Figure 1.** Magnetic resonance angiography.

with platelet count of 75 000/mm³. The splenic vein measured 4 millimeters. Iliac-mesenteric-caval shunting was performed with a 7 mm anastomosis. (Figure 2)

The patient received enoxaparin for five days and then was changed to acetylsalicylic acid. A postoperative ultrasound showed adequate and permeable bypass; spleen size 7 × 2.7 cm. A control endoscopy before discharge found G1 varices; platelet count: 168 000/mm³ (Tables 3 and 4).

**Figure 2.** Iliac-mesenteric-caval shunt.

CASE 2

Boy age 1 year 6 months of 37 weeks' gestation with Apgar score 5-7. He was hospitalized ten days. He was fitted with an umbilical catheter for 24 hours. His condition started with semi-liquid evacuations with mucus and blood; he was treated conservatively (Table 1). He was hospitalized four times for digestive tract bleeding at Hospital de Toluca. He was transferred to Instituto Nacional de Pediatría. An endoscopy showed G3 and G4 varices and congestive gastropathy (Table 2). A magnetic resonance angiography revealed cavernomatous degeneration of the portal vein, splenomegaly measuring 10.6 × 3.5, and hypersplenism, platelet count: 59 000/mm³ and the diameter of the splenic vein was 5 mm. Patient underwent iliac-mesenteric-caval shunting with 6 mm anastomosis (Figure 3).

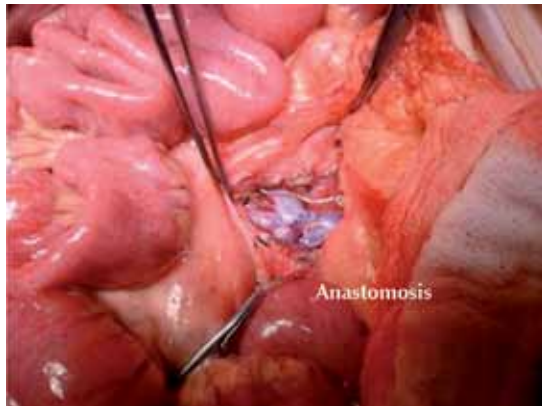


Figure 3. Iliac-mesenteric-caval shunt with 6 mm anastomosis.

He received enoxaparin for five days and then acetylsalicylic acid. A postoperative ultrasound showed adequate and permeable bypass; spleen 8.3 × 2.3 cm. The control endoscopy before discharge found reduction in grade of varices to grades 2 and 3. The platelet count was 101 000/mm³ (Tables 3 and 4).

Table 3. Comparison of results 5 days after surgery

	Case 1	Case 2
Ultrasound	Spleen: 7 × 2.7 cm Permeable anastomosis	Spleen: 8.3 × 2.3 cm Permeable anastomosis
Endoscopy	G1 esophageal varices	G2 and G3 esophageal varices
Platelet count	168,000/mm ³	101,000/mm ³

Table 4. Results during follow-up

	Case 1	Case 2
Doppler Ultrasonography (anastomosis)	Permeable	Permeable
Platelet count	187,000/mm ³	144,000/mm ³
Signs of bleeding	No	No
Postoperative time	13 months	11 months

DISCUSSION

The causes of portal hypertension at pediatric age are varied. In extra-hepatic manifestations portal cavernomatous transformation is more common than in intra-hepatic manifestations. Regardless of the cause, children with portal hypertension have a high risk of bleeding from varices, especially if portal vein pressure is above 28 mmHg.⁴ Children with portal hypertension have severe symptoms: recurrent digestive tract bleeding and hypersplenism.¹³

Portocaval shunting achieves excellent results in lowering pressure in gastric and esophageal blood vessels to normal levels.¹⁴

Surgical treatment should be considered in patients who have required transfusions or endoscopic procedures or patients with hypersplenism.¹³ Most patients are candidates for portosystemic shunting.⁴ An estimated 30 to 40% of patients with varices are in a compensated state, whereas 60% are in a decompensated state.¹⁵ Initial treatment of patients with bleeding consists of stabilizing them, to then perform a definitive treatment.¹⁶

Most decompensated patients will require some form of portosystemic shunting.¹⁷ Endoscopic ligation is effective to prevent initial bleeding in patients with moderate varices.¹⁵

Rupture of esophageal varices causes 70% of digestive tract bleeding in patients with portal hypertension.¹⁸ The general consensus reports that a majority of deaths occur in the first six weeks of hospitalization.¹⁹

In our two cases iliac-mesenteric-caval shunting was performed, despite the fact that the patients were not at the best age for it, given that even with medical treatment the symptoms persisted and the possibility of massive (life threatening)

digestive tract bleeding was very high. The evolution of both patients is satisfactory and will continue to be closely monitored.

CONCLUSION

Portosystemic shunting in patients under two years of age is a feasible alternative which improves clinical status in patients and lowers the risk of bleeding; however, long-term studies are needed to learn about the evolution of such patients.

REFERENCES

1. Bismuth H, Franco D, Alagille D. Portal Diversion for Portal Hypertension in Children. *Am Surg* 1980;192:18-24.
2. Montano-Loza A, Meza-Junco J. Patogenesis de la hipertensión portal. *Rev Invest Clin* 2005;57:596-607.
3. Antonio-Sandoval L, Yamamoto-Nagano A, Ortiz-Galvan RC, Diego-Perez J, Lorenzo-Hernandez A. Ventajas de la Derivación Esplenorrenal Distal vs otras derivaciones portosistémicas en pacientes pediátricos con Hipertensión Portal e Hiperesplenismo en un Hospital de Tercer Nivel de Atención. *Rev Mex de Cir Ped* 2008;15:106-13.
4. Shun A, Delaney DP, Martin HCO, Henry GM, Stephen M. Portosystemic Shunting for Paediatric Portal Hypertension. *J Pediatr Surg* 1997;32:489-93.
5. Karrer J. Portal hypertension. *Semin Pediatr Surg* 1992;1:134-44.
6. Sahni P, Pande GK, Nundy S. Extrahepatic portal vein obstruction. *Br J Surg* 1990;77:1201-2.
7. Terblanche J, Burroughs A, Kenneth EF. Controversies in the management of bleeding esophageal varices. *N Engl J Med* 1989;320:1393-8.
8. Santi P, Marion P. Techniques des derivations porto-caves. *Semin Hop Paris* 1953;29:2758-67.
9. Clatworthy H. A new type of portal to systemic venous shunt for portal hypertension. *Arch Surg* 1955;71:588.
10. Clatworthy H, Boles T. Extrahepatic portal bed block in children: pathogenesis and treatment. *Ann Surg* 1959;150:371-83.
11. Vargas-Gomez MA, Gonzalez-Castillo AD, Ramirez-Mayans JA, Mora-Tiscareno MA, Martinez-Sosa MC. Evaluación de la derivación mesentérico-iliaca y esplenorrenal en niños con hipertensión porta prehepática. *Rev Mex Cir Ped* 1994;1:59-70.
12. Alvarez F, Bernard O, Brunelle F, Hadchouel P, Odievre M, Alagille D. Portal obstruction in children II. Results of surgical portosystemic shunts. *J Pediatr* 1983;103:703-07.
13. Dasgupta R, Roberts E, Superina RA, Kim PC. Effectiveness of Rex shunt in the treatment of portal hypertension. *J Pediatr Surg* 2006;41:108-12.
14. Chen H, Ping W, Yang P, Yan JQ, Li QY, Ma D, et al. Long Term results of small-diameter proximal splenorenal venous shunt: a retrospective study. *World J Gastroenterol* 2011;17:3453-58.
15. Bosch J, Berzigotti A, Garcia-Pagan JC, Abraldes JG. The management of portal hypertension: Rational basis, available treatments and future options. *J Hepatol* 2008;48:68-92.
16. Gugig R, Rosenthal P. Management of Portal Hypertension in children. *Gastroenterol Rep* 2011;13:1176-84.
17. Botha JF, Campos BD, Grant WJ, Horslen SP, Sudan DL, Shaw BW, et al. Portosystemic Shunts in Children: A 15-Year Experience. *J Am Coll Surg* 2004;2:179-85.
18. Amico GD, De Franchis R, Cooperative Study Group. Upper Digestive Bleeding in Cirrhosis. Post-therapeutic Outcome and Prognostic Indicators. *J Hepat* 2003;38:599-612.
19. De Franchis R. Evolving Consensus in Portal Hypertension. Report of the Baveno IV Consensus Workshop on methodology of diagnosis and therapy in portal hypertension. *J Hepatol* 2005;43:167-76.