



## Niemann-Pick disease type B. Study of 3 cases and literature revision

### ABSTRACT

**Objective:** To describe the course of type B Niemann-Pick disease (ENP-B) by following the evolution of three pediatric patients.

**Methods:** Three patients, two of them male, age between two and eleven years, with type B Niemann-Pick disease were evaluated periodically by physic exam and laboratory: hematologic indices, lipid profile, hepatic function tests; Radiologic studies: chest X-ray, abdominal ultrasound, cranial computed tomography, echocardiogram. Histologic exams: hepatic biopsy, bone marrow aspirate. We also obtained information on intercurrent pathologies.

**Results:** Symptoms started at around 3 years (2-5 years) and the diagnosis was made approximately at the age of 5 years 3 months (2-11 years), based on clinical findings suggestive of ENP-B; on foam cells in bone marrow aspirate in the three patients, in hepatic biopsy in two of them and in acid sphingomyelinase determination in three. The coexistent conditions were: hepatosplenomegaly in three; neurologic disorder in two; bone disorder in one; pulmonary disorder in two; liver disorder in three; affected hematological indices in three; lipid abnormalities in three; cardiac involvement in one; ocular manifestations in one; growth retardation in three. In none of the families were detected consanguinity nor endogamy.

**Conclusions:** This study shows the multisystemic character and the clinic variability in the type B Niemann-Pick disease, which is mainly characterized by hepatosplenomegaly and liver dysfunction. Patients have a progressive hypersplenism, atherogenic lipid profile and gradual deterioration of pulmonary function, among other systemic manifestations. To confirm the diagnosis it is required to determine acid sphingomyelinase. To date, there are no useful biomarkers to evaluate the disease activity. Enzyme replacement therapy is still on research.

**Key words:** Niemann-Pick disease, cherry red maculae, hepatosplenomegaly, liver dysfunction.

Jorge Zarco-Román<sup>1</sup>  
Alva Nydia García-Pérez<sup>2</sup>  
Paulina Andrade-Aldama<sup>2</sup>  
Luis Carbajal-Rodríguez<sup>3</sup>  
Raymundo Rodríguez-Herrera<sup>1</sup>

<sup>1</sup>Physician assigned to the Internal Medicine service.

<sup>2</sup>Pediatrician, former resident.

<sup>3</sup>Head of the Internal Medicine service.

Instituto Nacional de Pediatría, México, D.F.

Received: February, 2013

Accepted: November, 2013

### Correspondence

Dr. Jorge Zarco Roman  
Insurgentes Sur 3700-C  
Mexico DF  
Tel. 10840900 extension 1357, Mobile: 5525155681  
elzarco07@yahoo.com.mx

### This article must be quoted

Zarco-Román J, García-Pérez AN, Andrade-Aldama P, Carbajal-Rodríguez L, Rodríguez-Herrera R. Enfermedad de Niemann-Pick tipo B. Estudio de tres casos y revisión de la literatura. Acta Pediátr Mex 2014;35:30-37.

Niemann-Pick disease is a lysosomal deposit disorder with recessive autosomic inheritance, with accumulation of sphingomyelin and lipids in the cells of the monocyte-macrophage system and the brain, due to the deficiency of acid sphingomyelins.<sup>1,2</sup> The estimated incidence is 1: 80,000 in live newborns of all ethnic groups, unlike Niemann-Pick disease type A, which has greater predisposition in Ashkenazi Jews.<sup>2,3</sup>

It is characterized by hepatosplenomegaly,<sup>2,4</sup> at times dyslipidemias, and thrombocytopenia secondary to hypersplenism.<sup>2,5</sup> Gradual deterioration of pulmonary function,<sup>3,6</sup> and retardation of growth and eye alterations are also observed.<sup>7,8</sup> Most cases are without neurological anomalies.<sup>9</sup>

To confirm the diagnosis it is necessary to prove deficit of the enzyme acid sphingomyelinase in leukocytes or fibroblasts.<sup>10</sup> There is no specific treatment at present, it is purely symptomatic.<sup>11</sup>

## MATERIAL AND METHODS

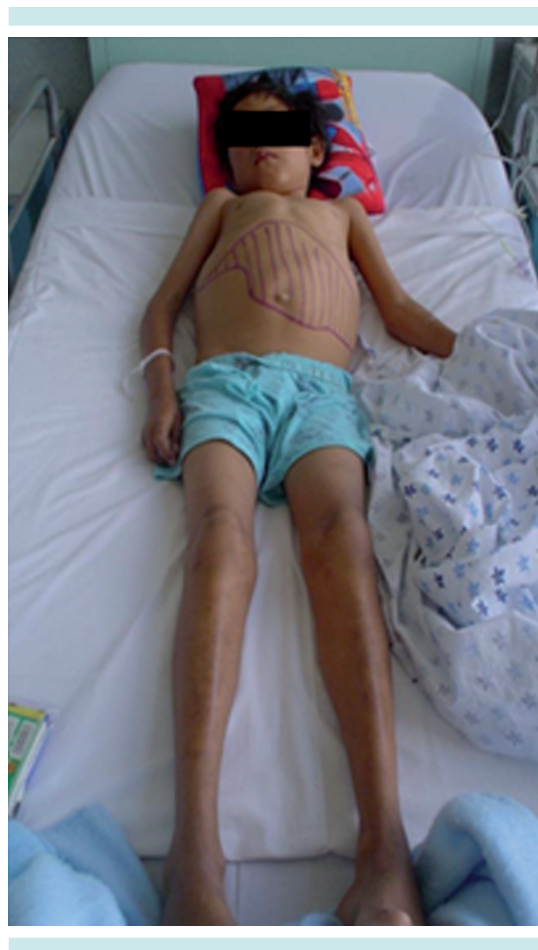A retrospective study of clinical records of three patients with type B Niemann-Pick disease, diagnosed at the National Institute of Pediatrics Department of Internal Medicine in the period 2001-2011. The clinical evolution and data obtained from laboratory tests, x-ray studies, examining room tests, and histopathology were described. Two male subjects, between 2 and 11 years of age; there was no family consanguinity.

## RESULTS

Symptoms started at around 3 years (2-5 years) and the diagnosis was established around 5 years 3 months (2-11 years).

The three subjects had hepatosplenomegaly, diagnosed clinically and by abdominal ultrasound (Figure 1). Two patients had hypersplenism and portal hypertension. All had elevation of

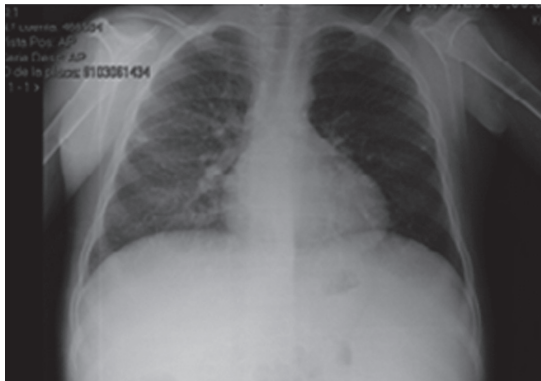
transaminases and only one had elevation of bilirubins. Detention of weight and height was observed. Thrombocytopenia was found in the three patients, and in two anemia, leukopenia, and prolonged clotting time (Table 1). There was pulmonary compromise in two subjects, without significant clinical manifestations. Chest x-rays showed a diffuse micronodular infiltrate in both cases. (Figure 2) In two patients there were neurological alterations, characterized by mild psychomotor retardation. One patient had heart involvement, identified by echocardiogram: right ventricular dilation, with FEV1 of 74%. Ophthalmological examination observed



**Figure 1.** Patient with NPD-B showing hepatosplenomegaly.

**Table 1.** Clinical characteristics of the group of patients with Niemann-Pick disease type B

Clinical characteristic	Patient 1	Patient 2	Patient 3
Hepatosplenomegaly	X	X	X
Hepatic involvement	X	X	X
Retardation of growth	X	X	X
Blood involvement	X	X	X
Pulmonary involvement	X	X	
Neurological involvement	X	X	
Cardiac involvement		X	
Cherry red spot		X	
Bone involvement		X	

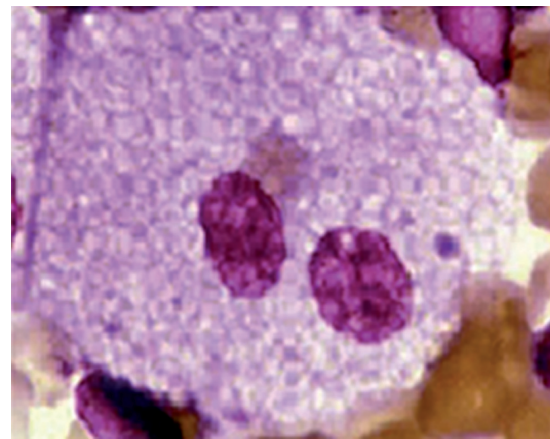
**Figure 2.** Chest x-ray of a patient with Niemann-Pick disease type B; observe the diffuse micronodular infiltrate.

a cherry red spot in one patient. The lipid profile was altered in the three patients, with elevation of cholesterol, triglycerides, and LDL and reduction of HDL. (Table 2). In one case osteopenia was observed in the x-ray studies.

*Histopathological studies.* In the three patients the bone marrow aspirate showed foam cells (Figure 3). Blood biopsy of two patients revealed foam cells, and steatosis and hepatic fibrosis were found in one of them. The determination of blood acid sphingomyelinase revealed a frank reduction in the three subjects, in one a value of 26 pmol/spot\*20 h; in another 32 pmol/spot\*20 h, and in the third 14 pmol/spot\*20 h, with

**Table 2.** Alterations in laboratory and histological tests

Alteration	Patient 1	Patient 2	Patient 3
Anemia	No	Yes	Yes
Thrombocytopenia	Yes	Yes	Yes
Leukopenia	No	Yes	Yes
Prolongation of clotting times	No	Yes	Yes
Alteration of liver enzymes	Yes	Yes	Yes
Alteration of lipid profile	Yes	Yes	Yes
Altered liver biopsy	Yes	Yes	No
Bone marrow aspirate: foam cells	Yes	Yes	Yes
Determination of acid sphingomyelinase	Deficient	Deficient	Deficient

**Figure 3.** Foam cells in bone marrow aspirate from a patient with Niemann-Pick disease type B.

reference values of 200-3500 pmol/spot\*20 h, confirming the diagnosis. In no subject was it determined if there was any mutation in the acid sphingomyelinase gene.

## ANALYSIS

Niemann-Pick disease was first described by German pediatrician Albert Niemann in 1914.



In 1927 the German pathologist Ludwig Pick described it as a unique disease, histologically differentiating it from Gaucher disease.<sup>12,13</sup>

Different mutations of the sphingomyelin phosphodiesterase-1 (SMPD1) gene, located in chromosome 11p15.1-11p15.4, cause deficient activity of lysosomal sphingomyelinase and are responsible for Niemann-Pick disease types A and B.<sup>11, 14</sup> Niemann-Pick disease type B appears later and is less serious than type A, with high probability of survival into adult age. Studies comparing sphingomyelinase activity reveal greater activity of the enzyme in patients with Niemann-Pick disease type B, unlike the undetectable activity shown in patients with Niemann-Pick disease type A.<sup>2,4,15</sup>

Niemann-Pick disease type B is characterized by hepatosplenomegaly in childhood or adolescence; some cases have antecedents of neonatal hepatitis. Liver involvement may be serious and evolve into chronic liver disease and hepatic fibrosis. Signs of cirrhosis may be found, or even fulminant hepatic failure, which is more common in adult age.<sup>2,4</sup> Two of our subjects had portal hypertension and one of them esophageal varicose veins which caused bleeding of the digestive tract and anemia, which required multiple transfusions and sclerosing treatment of the varicose veins. Liver biopsies of two subjects showed foam cells, and in one of them steatosis and fibrosis, as reported in the literature. In patients with Niemann-Pick disease type B elevation of transaminases and bilirubins has also been described,<sup>2,16</sup> like in the cases reported herein.

The hemogram reported reduction in platelets, hemoglobin, and leukocytes, possibly due to hypersplenism, which tends to be progressive, with risk of splenic rupture, as a result of which such patients should avoid contact sports.<sup>2,11</sup> The clinical consequences of leukopenia are, mainly, respiratory tract infections caused by encapsu-

lated microorganisms. Due to thrombocytopenia, patients experience episodes of bleeding, petechiae, and ecchymosis.<sup>2</sup> One of our subjects with thrombocytopenia (around 50,000 platelets/mm<sup>3</sup>) had episodes of bleeding of the digestive tract and epistaxis, requiring transfusion of erythrocyte and platelet concentrates.

In Niemann-Pick disease type B we observe gradual deterioration of pulmonary function due to accumulation of lipid laden macrophages in the alveolar septums, in the bronchial walls and the pleura, developing a restrictive pattern which worsens progressively. This can be found in an asymptomatic patient and in individuals who are oxygen dependent or have respiratory insufficiency.<sup>17,18</sup>

Mendelson et al.<sup>18</sup> studied 53 patients with chest x-rays and thin slice CAT, spirometry (forced vital capacity, FEV1), and lung diffusing capacity for carbon monoxide. The chest x-ray and CAT showed interstitial lung disease in 90% and 98% of the patients, respectively. In six of those patients pulmonary nodules were observed. In patients with Niemann-Pick disease type B findings the image nodules observed are not necessarily correlated with pulmonary function. In two of our subjects diffuse reticulonodular infiltrate was observed in the chest x-ray and in one of them a pulmonary nodule, not correlated with clinical data because they were found to be asymptomatic. It was not possible to perform pulmonary function tests on them.

As regards pulmonary involvement, few treatment modes have been identified, none of them specific. Lung lavage is an option to prevent lipid deposit; however, this treatment has been seen to achieve only temporary improvement, because inflammatory cells tend to repopulate the airway, producing the same or worse symptoms.<sup>3,6,11</sup>

Other systemic manifestations are: low weight and height, with retardation of skeletal growth,<sup>2,7</sup>

which were corroborated in our subjects. Most adolescents with con Niemann-Pick disease type B also have osteopenia or osteoporosis.<sup>17</sup>

Ocular anomalies have been found in 30% of individuals with Niemann-Pick disease type B: cherry red spot and macular halo. The characteristic cherry red spot forms when there is abundant accumulation of lipids in the retinal ganglion cells, which produces a white ring around the fovea, which is red.<sup>8</sup> This sign was present in one of our subjects, and was seen in the fundus examination.

Most patients with this disease do not have neurological anomalies. However, at the end of infancy some may present varying degrees of central nervous system involvement, including cerebellar and extrapyramidal signs, nistagmus, mental retardation, psychiatric disorders, and peripheral nerve disease. In a series of 64 patients with Niemann-Pick disease type B neurological anomalies were observed in 30% of cases, of which 22% were minor and not progressive, while 8% showed global and progressive deterioration. In the latter group, the appearance of neurological alterations occurred between two and seven years of age.<sup>9</sup> In two of our subjects, neurological alterations were found, related to problems at birth and not the disease, because both had neonatal hypoxia and one of them was premature and had hyperbilirubinemia which required exsanguinotransfusion. The brain CAT showed cortical atrophy in both cases.

AS regards cardiological issues, patients may present certain abnormalities, such as: sinus bradycardia, ventricular hypertrophy, and conduction disorders. Valve alterations have been observed in the echocardiogram, including: mitral and aortic insufficiency and pulmonary hypertension.<sup>16</sup> Only one of our subjects had right ventricular hypertrophy, without hemodynamic repercussion.

The literature reports that in such patients lipid anomalies are often found, in particular low HDL cholesterol, hypertriglyceridemia, and high LDL cholesterol. McGovern et al. found that most of their patients had an atherogenic lipid profile and 74% low HDL; 41% high concentrations of total cholesterol; 62% high triglycerides; 46% high LDL; and 62% high very low density (VLD) lipoprotein.<sup>5</sup> Our three subjects had alterations in lipid profile, with high cholesterol, triglycerides, and LDL, and low HDL. They were given dietary treatment and neither statins nor fibrates were indicated, because it has been reported that they do not substantially modify lipid concentrations and may increase transaminases, and therefore are contraindicated.<sup>2,19</sup>

Patients with the clinical manifestations described may undergo a bone marrow aspirate to check for foam cells (large macrophages with finely vacuolated eccentric nucleus and foam appearance); the study is not pathognomonic. To confirm the diagnosis it is necessary to prove acid sphingomyelinase deficit in leukocytes or fibroblasts.<sup>10,20</sup>

To date, in Niemann-Pick disease more than 40 mutations of the sphingomyelinase gene types A y B have been identified. Often, mutation DR608 has been identified in patients with Niemann-Pick disease type B in different populations.<sup>8,14,21</sup> Patients homozygous for DR608 tend to have normal weight and height, with hepatosplenomegalia and considerable retardation in bone age.<sup>7</sup> In our subjects it was not possible to identify mutations.

Some biomarkers, such as chitotriosidase and CCL18 (CC chemokine ligand 18) are found to be high in most patients with Niemann-Pick disease type B, although there is more experience of their usefulness in Gaucher disease. Both biomarkers may help to detect lipid laden pathologic macrophages, to determine which patients





have disease activity or suffer relapses. Other authors report that their usefulness is less.<sup>16,22</sup> In our subjects there was no opportunity to test for these biomarkers.

In view of the low prevalence of the disease it is important that physicians of first contact recognize it. In relation to treatment, it is recommended that periodic evaluation include: growth and development, nutritional status, status of pulmonary function, and intentional search for abdominal signs and symptoms and neurological alterations. At present there is no specific treatment for Niemann-Pick disease type B, only control of symptoms to improve quality of life. Today enzyme replacement therapy is indicated in patients with some lysosomal deposit disorders; for Niemann-Pick disease type B it is in investigation.<sup>11,16</sup>

Today there is a constant search for new treatments; there are several in the preclinical evaluation phase, which could offer hope in the future. Some studies indicate that hematopoietic stem cell transplant is feasible and potentially beneficial when performed before the appearance of severe liver and pulmonary damage, underscoring the importance of establishing diagnosis early. Complications have been described, such as: transplant rejection, chronic skin diseases, and renal tubular dysfunction.<sup>23,24</sup> Liver transplant has also been established in patients with Niemann-Pick disease type B, although the results have not been described adequately.<sup>11</sup>

Because Niemann-Pick disease type B is a recessive autosomic disorder, the probability in each pregnancy of having an affected child is 25%. Prenatal evaluation is recommended because sphingomyelinase activity can be measured in fibroblasts of amniotic fluid or by means of molecular genetic tests.<sup>25</sup>

## REFERENCES

1. Mc Govern M, Aron A, Brodie S, Desnick R, Wasserstein M. Natural history of Type A Niemann Pick disease: possible endpoints for therapeutic trials. *Neurology* 2006;66:228-232.
2. Wasserstein M, Desnick R, Schuchman E, Hossain S, Wallenstein S, Lamm C, et al. The Natural History of Type-B Niemann-Pick Disease: Results from a 10-year longitudinal study. *Pediatrics* 2004;114:672-677.
3. Guillemot N, Troadec C, Billette de Villemeur T, Clement A, Fauroux B. Lung Disease in Niemann-Pick disease. *Pediatric Pulmonology* 2007;42:1207-1214.
4. Takahashi T, Akiyama K, Tomihara M, Tokudome T, Nishinomiya F, Tazawa Y, et al. Heterogeneity of liver disorder in type B Niemann-Pick disease. *Hum Pathol* 1997;27:385-388.
5. Mc Govern M, Pohl-Worgall T, Deckelbaum R, Simpson W, Mendelson D, Desnick R, et al. Lipid abnormalities in children with types A and B Niemann Pick Disease. *J Pediatr* 2004;145:77-81.
6. Uyan Z, Karadag B, Ersu R, Kiyani G, Kotiloglu E, Sirvanci S, et al. Early pulmonary Involvement in Niemann-Pick Type B Disease: Lung Lavage is not useful. *Pediatric Pulmonology* 2005;40:169-172.
7. Wasserstein M, Larkin A, Glass R, Schuchman E, Desnick R, McGovern M. Growth restriction in children with type B Niemann Pick disease. *J Pediatr* 2003;142:424-428.
8. McGovern M, Wasserstein M, Aron A, Desnick R, Schuchman E, Brodie S. Ocular Manifestations of Niemann-Pick Disease Type B. *Ophthalmology* 2004;111:1424-1427.
9. Wasserstein M, Aron A, Simonaro C, Brodie S, Desnick R, McGovern M. Acid sphingomyelinase Deficiency: Prevalence and characterization of an intermediate phenotype of Niemann-Pick disease. *J Pediatr* 2006;149:554-559.
10. Harzer K, Rolfs A, Bauer P, Zschiesche M, Mengel E, Backes J, et al. Niemann-Pick Disease type A and B are clinically but also enzymatically heterogeneous: pitfall in the laboratory diagnosis of sphingomyelinase deficiency associated with the mutation Q292K. *Neuropediatrics* 2003;34:301-306.
11. Schuchman E. The pathogenesis and treatment of acid sphingomyelinase-deficient Niemann-Pick disease. *J Inher Metab Dis* 2007;654-663.
12. Niemann A. Ein unbekanntes Krankheitsbild. *Jahrbuch für Kinderheilkunde* 1914;79:1-10.
13. Pick L. Der Morbus Gaucher und die ihm ähnlichen krankheiten (die lipoidzellige Splenohepatomegalie Typus Niemann und die diabetische Lipoidzellenhypoplasie der Milz). *Ergebnisse der Inneren Medizin und Kinderheilkunde* 1926;29:519-27.
14. Simonaro C, Park J, Eliyahu E, Shtraizent N, McGovern M, Schuchman E. Imprinting at the SMPD1 Locus: Implications

- for Acid Sphingomyelinase-Deficient Niemann-Pick disease. *Am J Genet* 2006;78:865-870.
15. Graber D. Accurate differentiation of neuronopathic and nonneuronopathic forms of Niemann-Pick disease by evaluation of the effective residual lysosomal sphingomyelinase activity in intact cells. *J Neurochem* 1994;63:1060.
  16. McGovern M, Wasserstein M, Giugliani R, Bembi B, Vanier M, Mengel E, et al. A prospective, cross-sectional survey study of the natural history of Niemann-Pick disease type B. *Pediatrics* 2008;122:341-349.
  17. Simpson W, Mendelson D, Wasserstein M, McGovern M. Imaging manifestations of Niemann-Pick Disease type B. *AJR* 2010;194:12-19.
  18. Mendelson D, Wasserstein M, Desnick R, Glass R, Simpson W, Skloot G, et al. Type B Niemann-Pick Disease: Findings at chest radiography, thin section CT, and pulmonary function testing. *Radiology* 2006;238:339-345.
  19. Choi J, Shin Y, Kim G, Hong S, Yoo H. Treatment of hyperlipidemia associated with Niemann-Pick disease type B by fenofibrate. *Eur J Pediatr* 2006;165:138-139.
  20. Zarco Roman J. Enfermedad de Niemann-Pick. In: *Errores innatos del metabolismo en el niño*. Mexico:McGraw Hill, 2013;127-136.
  21. Desnick J, Kim J, He X, Wasserstein M, Simonaro C, Schuchman E. Identification and Characterization of eight novel SMPD1 mutations causing types A and B Niemann-Pick Disease. *Mol Med* 2010;16:316-321.
  22. Brinkman J, Wijburg F, Hollak C, Groener J, Verhoek M, Scheij S, et al. Plasma chitotriosidase and CCL18: Early biochemical surrogate markers in type B Niemann-Pick disease. *J Inher Metab Dis* 2005;28:13-20.
  23. Shah A, Kapoor N, Crooks G, Parkman R, Weinberg K, Wilson K, et al. Successful Hematopoietic stem cell transplantation for Niemann-Pick Disease Type B. *Pediatrics* 2005;116:1022-1025.
  24. Schneiderman J, Thormann K, Charrow J, Kletzel M. Correction of Enzyme Levels With Allogeneic Hematopoietic Progenitor Cell Transplantation in Niemann-Pick Type B. *Pediatr Blood Cancer* 2007;49:987-989.
  25. Vanier M. Prenatal diagnosis of Niemann-Pick diseases type A, B and C. *Prenat Diagn* 2002;22:630.