



# Evaluation of dystrophic calcification in juvenile dermatomyositis and systemic sclerosis

Marimar Saez-de Ocariz<sup>1</sup>  
Angélica Carrillo-Rincón<sup>1</sup>  
Chiharu Murata<sup>2</sup>  
Alonso Gutiérrez-Hernández<sup>3</sup>  
Rosa María Palma-Rosillo<sup>4</sup>  
Nelly Altamirano-Bustamante<sup>5</sup>

<sup>1</sup> Dermatology Service

<sup>2</sup> Research Methodology

<sup>3</sup> Immunology Service

<sup>4</sup> Nuclear Medicine Service

<sup>5</sup> Endocrinology Service

Instituto Nacional de Pediatría, México, D.F.

## ABSTRACT

**Background:** Dystrophic calcification is associated with juvenile dermatomyositis and progressive systemic sclerosis. The clinical diagnosis is established with detection of subcutaneous and petrous nodules. Conventional x-ray methods may evidence calcium deposits; however, in the case of incipient deposits x-ray may be insufficient. There are studies that use Tc99-MPD labeled bone scintigraphy to identify dystrophic calcification.

**Objectives:** Estimate the frequency of dystrophic calcification in patients with juvenile dermatomyositis and progressive systemic sclerosis and CREST syndrome, and the concordance between the diagnosis of dystrophic calcification obtained by physical exploration and that obtained by scintigraphy.

**Patients and methods:** A comparative, observational, and transverse study conducted in patients of one and the another gender, between 5 and 17 years of age, with diagnosis of juvenile dermatomyositis, progressive systemic sclerosis, and CREST syndrome to detect dystrophic calcification by physical exploration and scintigraphy. Fisher's exact test was performed to evaluate the association between the two diagnostic methods, and the Kappa test was used for the level of concordance and analysis of distribution by group and extent of dystrophic calcification. The sensitivity and specificity of scintigraphy in detecting dystrophic calcification in soft tissues, bony protrusions, costal arches and vertebrae were also estimated.

**Results:** The overall incidence of calcinosis was 80%. In 16 patients dystrophic calcification was detected by dermatological physical exploration and in 9 patients by scintigraphy. No association or concordance was found between the findings from physical exploration and scintigraphic findings. The latter have 37.5% sensitivity for detection of dystrophic calcification in soft tissues and 43.8% in bony protrusions, and are suitable for detection in costal arches.

**Conclusions:** Dermatological exploration and scintigraphy are complementary tools for detecting dystrophic calcification.

**Key words:** dystrophic calcification, juvenile dermatomyositis, progressive systemic sclerosis, scintigraphy.

Received: September, 2013

Accepted: November, 2013

## Correspondence

Dr. Marimar Saez de Ocariz  
Servicio de Dermatología  
Instituto Nacional de Pediatría  
Insurgentes Sur 3700 C  
04530 Mexico DF  
Telephone: 1084-5528  
mariadelmars@prodigy.net.mx

## This article must be quoted

Saez-de Ocariz M, Carrillo-Rincon A, Murata Ch, Gutierrez-Hernandez A, Palma-Rosillo RM, Altamirano-Bustamante N. Evaluación de la calcinosis distrófica en dermatomiositis juvenil y esclerosis sistémica. Acta Pediat Mex 2014;35:7-14.

Dystrophic calcification is a chronic condition characterized by buildup of crystals of hydroxyapatite or amorphous calcium phosphate<sup>1,2</sup> which appears in previously damaged or devitalized skin and soft tissues, even despite normal metabolism of calcium and phosphorous.<sup>2-4</sup> Dystrophic calcification is associated with autoimmune diseases of connective tissue and may be a cause of pain and functional disability.<sup>1</sup> The probability of developing dystrophic calcification varies among different autoimmune diseases of connective tissue, and is primarily associated with juvenile dermatomyositis and progressive systemic sclerosis and CREST syndrome,<sup>1</sup> with incidence of 30-70%<sup>5</sup> and 25-40%,<sup>6</sup> respectively.

Diagnosis of dystrophic calcification can be achieved by physical examination with detection of petrous subcutaneous nodules, which may ulcerate and release whitish matter. However, deep deposits or smaller nodules may not be detected in a physical examination. Image studies to detect calcium deposits include: simple x-ray,<sup>7</sup> computed axial tomography, magnetic resonance, and recently Tc<sup>99m</sup>MDP labeled scintigraphy.<sup>8</sup>

Because there are no studies that analyze the real incidence of dystrophic calcification — which may be under-diagnosed — determined by physical exploration and a radiological method, this article seeks to estimate the incidence of dystrophic calcification in this group of patients and the concordance between the diagnosis of dystrophic calcification obtained by physical exploration and that obtained by bone scintigraphy.

## PATIENTS AND METHODS

A comparative, observational, transverse study in which patients of one and the other gender, between 5 and 17 years of age, with diagnosis of juvenile dermatomyositis and progressive sys-

temic sclerosis and CREST syndrome attended in the service over a two-year period were included. All the patients underwent a complete physical exploration — by a trained dermatologist — in search of sites and extent of dystrophic calcification, and a clinical and image file was created for each one. Bone scintigraphies of all the subjects were taken in search of dystrophic calcifications. The findings observed in the physical exploration and scintigraphies were recorded in comparative diagrams depending on the anatomic sites affected. Each anatomic segment was divided in sections to determine not only the presence or absence of calcinosis, but also its localization and extent by both diagnostic methods, to compare the differences in findings between the two.

The study was approved by the National Institute of Pediatrics Research and Ethics Committees, and in all cases, an informed consent form was signed, and when required an assent form (in patients over 12 years of age).

The statistical analysis included Fisher's exact test to evaluate the association between the two diagnostic methods, the Kappa test to evaluate the level of concordance between the two diagnostic methods, and an analysis of distribution by group of the extent of calcinosis cutis with both diagnostic methods. We also estimated the sensitivity and specificity of scintigraphy for detecting dystrophic calcification in soft tissues, bony protrusions, costal arches, and vertebrae.

## RESULTS

Twenty patients were included, 17 with juvenile dermatomyositis, 2 with progressive systemic sclerosis, and 1 with superimposition of juvenile

dermatomyositis and progressive systemic sclerosis. The overall incidence of calcinosis (findings from the physical exploration combined with those from scintigraphy) was 80%; that of calci-

nosis identified by physical exploration was also 80%, and by scintigraphy 45%.

Dystrophic calcification was detected by dermatologic physical exploration in 16 patients: 13 with juvenile dermatomyositis, two with progressive systemic sclerosis, and one with superimposition (Table 1). Calcinosis was localized in 3 cases, disseminated in 10, and severe and disabling in 3 patients (Table 2). Scintigraphy showed calcinosis in only 9 patients, reporting normal findings in a patient with localized calcinosis and in 4 patients with disseminated calcinosis (Table 2). No association was found between the findings of the physical exploration and scintigraphic findings ( $p=0.852$ ).

The localization of dystrophic calcification in the 9 cases in which it was confirmed by both methods did not show concordance in 8 and

showed only partial concordance in one of them ( $\kappa = 0.0384$ ) (Table 2).

No correlation was found between the extent of calcinosis cutis determined by physical exploration and scintigraphic findings ( $p = 0.27$ ) (Figure 1).

If detecting dystrophic calcification by physical exploration is the reference pattern, scintigraphy has 37.5% sensitivity (0% specificity) for detection in soft tissues and 43.8% (0% specificity) for detection in bony protrusions, and is suitable for detecting dystrophic calcification in costal arches and vertebral bodies that are not found by physical exploration.

## ANALYSIS

Dystrophic calcification is observed in 30 to 70% of patients with juvenile dermatomyositis<sup>5</sup>

**Table 1.** General characteristics of subjects

| n  | Gender | Age at time of inclusion in the study | Diagnosis | Age of onset of disease | Dystrophic calcification* | Age of onset of calcinosis |
|----|--------|---------------------------------------|-----------|-------------------------|---------------------------|----------------------------|
| 1  | F      | 17 years                              | JDM/PSS   | 14 years                | Yes                       | 15 years                   |
| 2  | F      | 15 years                              | JDM       | 11 years                | Yes                       | 11 years                   |
| 3  | F      | 11 years                              | JDM       | 8 years                 | Yes                       | 8 years                    |
| 4  | F      | 13 years                              | PSS       | 10 years                | Yes                       | 10 years                   |
| 5  | F      | 10 years                              | JDM       | 7 years                 | Yes                       | 10 years                   |
| 6  | F      | 5 years                               | JDM       | 2 years                 | Yes                       | 8 years                    |
| 7  | F      | 9 years                               | JDM       | 8 years                 | No                        | N.A.                       |
| 8  | F      | 8 years                               | JDM       | 5 years                 | No                        | N.A.                       |
| 9  | F      | 9 years                               | JDM       | 6 years                 | Yes                       | 8 years                    |
| 10 | F      | 8 years                               | JDM       | 4 years                 | Yes                       | 7 years                    |
| 11 | M      | 5 years                               | JDM       | 3 years                 | Yes                       | 5 years                    |
| 12 | F      | 14 years                              | JDM       | 8 years                 | Yes                       | 8 years                    |
| 13 | F      | 8 years                               | JDM       | 5 years                 | Yes                       | 7 years                    |
| 14 | F      | 11 years                              | JDM       | 8 years                 | Yes                       | 10 years                   |
| 15 | M      | 5 years                               | JDM       | 3 years                 | No                        | N.A.                       |
| 16 | F      | 6 years                               | PSS       | 4 years                 | Yes                       | 5 years                    |
| 17 | F      | 12 years                              | JDM       | 4 years                 | Yes                       | Unknown                    |
| 18 | F      | 12 years                              | JDM       | 11 years                | No                        | 11 years                   |
| 19 | F      | 16 years                              | JDM       | 10 years                | Yes                       | 11 years                   |
| 20 | F      | 7 years                               | PSS       | 6 years                 | Yes                       | 6 years                    |

\* Determined by physical exploration

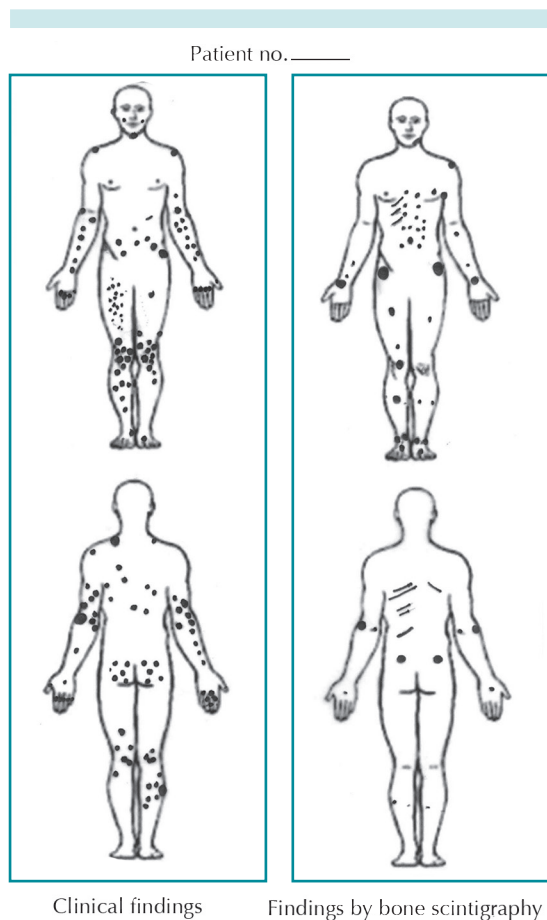
JDM = Juvenile dermatomyositis; PSS = Progressive systemic sclerosis.

**Table 2.** Findings of physical exploration and bone scintigraphy

| n  | Physical exploration   | Bone scintigraphy   |
|----|--|---|
| 1  | Calcinosis disseminated to all bodily segments, from millimetric neoformations to others measuring several centimeters, with discharge of whitish matter | Increased bone metabolic activity in the knees and left ankle, focal areas of abnormal uptake in soft tissues of both hands, and in the left hemithorax at the level of the first, sixth, and seventh costal arches |
| 2  | Calcinosis disseminated to: trunk, abdomen, iliac crests, elbows, fingers, upper third of thighs, knees and anterior face of legs                        | Several areas of nodular hyper-uptake in the left shoulder and underarm, on the fourth and fifth rib on the left side and third rib on the right side.  |
| 3  | Calcinosis in the left elbow   | Normal  |
| 4  | Calcinosis in elbows, knees, and fingers of the left hand  | Increased osteogenic activity in the right coxofemoral joint  |
| 5  | Calcinosis in helix of the right ear   | Normal  |
| 6  | Calcinosis in malar regions, mandibular branches, left elbow and left finger   | Normal  |
| 7  | No calcinosis  | Normal  |
| 8  | No calcinosis  | Normal  |
| 9  | Calcinosis in right elbow and knee   | Normal  |
| 10 | Calcinosis in right palm, elbows, and knees.   | Two areas of abnormal concentration of the radiopharmaceutical in soft tissues, one above the left iliac crest and the other in the soft tissues of the upper third of the right leg.                               |
| 11 | Calcinosis in the back of hands and elbows   | Incipient lesion in L-3   |
| 12 | Calcinosis in fingers of the right hand, second and third fingers of the left hand, and both knees   | Increased bone metabolic activity in the left temporomandibular joint, in the costochondral joints of the bilateral costal arches, ischiopubic ramus, ankles, and sacroiliac joints.                                |
| 13 | Calcinosis in elbows, metacarpophalangeal joints, and region of iliac crests   | Osteogenic hyperactivity in the right proximal femoral region, last anterior costal arches on the right side, and tibial diaphysis of the left side.  |
| 14 | Calcinosis affecting both legs, with predominance in the left pretibial region.  | Normal  |
| 15 | No calcinosis  | Normal  |
| 16 | Diffuse calcinosis with millimetric neoformations in the left arm and both thighs  | Increased bone metabolic activity in the costochondral joints of the bilateral costal arches  |
| 17 | Calcinosis in metacarpophalangeal joints   | Normal  |
| 18 | No calcinosis  | Normal  |
| 19 | Calcinosis in elbows, forearms, knees, popliteal fossas, posterior trunk, posterosuperior third of legs, glutei and perianal region                      | Hyper-uptake in large joints  |
| 20 | Millimetric calcinosis in left elbow and abdomen   | Normal  |

and in 25 to 40% of patients with progressive systemic sclerosis.<sup>6</sup> In our cases we found a very high incidence of dystrophic calcification, of even 80% with the combination of both diagnostic methods. The reasons for such

a high incidence may be that all the investigators were sensitized to search for it and that, in fact, dystrophic calcification is under-reported because it is considered irrelevant to establish therapeutic considerations.



**Figure 1.** Schematic and comparative representation (clinical findings and bone scintigraphy) of sites affected by dystrophic calcification in 16 patients.

In general terms, dystrophic calcification appears between 1 and 3 years after the onset of juvenile dermatomyositis or progressive systemic sclerosis/CREST, although in some cases onset may be delayed for up to 20 years. On the one hand, detection is important because dystrophic calcification is associated with delays in diagnosis and in starting treatment for autoimmune disease.<sup>9,10</sup> On the other hand, because the natural evolution of dystrophic calcification is variable and unpredictable, and may be associated with

numerous sequelae, detection is important to choose treatment for the underlying autoimmune disease, and for dystrophic calcification itself, before it causes greater morbidity.<sup>8</sup>

Dystrophic calcification can be detected by physical exploration, although there are various image studies that help evidence calcium deposits, as has been described by Nunley and Jones:<sup>8</sup> conventional x-ray, computed axial tomography, magnetic resonance, and bone scintigraphy.

Image studies with conventional x-ray can identify the pattern of soft tissue calcification and aid in diagnosing dystrophic calcification. Blane et al.<sup>11</sup> classified radiographic findings of dystrophic calcification in patients with juvenile dermatomyositis in four patterns: superficial plates or nodules on skin and soft tissues; deep nodular deposits extending to muscles; deposits along the fascial planes of muscles and tendons, and firm deposits covering the entire bodily surface (exoskeleton).

However, to detect calcification in deeper soft tissues, CAT is considered more sensitive and specific than conventional x-ray. CAT has the added advantage of demarcating ossifying lesions and the calcification plane.<sup>8,12</sup> In the case of magnetic resonance, its usefulness is limited in the presence of already calcified structures; however, the images obtained may be useful in detecting edema or inflammation of skin, soft tissues, or fascia before dystrophic calcification appears.<sup>8,13,14</sup>

In the case of scintigraphy labeled with compounds of radioactive phosphate, several authors have shown that abnormal distribution of radioactive labeling is useful for initial evaluation and monitoring the severity and extent of dystrophic calcification associated with various autoimmune diseases, in particular in patients with juvenile dermatomyositis.<sup>14-18</sup>

In our series of patients, it is noteworthy that the bone scintigraphy detected dystrophic calcification in only 56% of cases in which its existence was clinically proven. In addition to the absence of association between clinical and image findings, there was a marked lack of concordance between localization and extent of dystrophic calcification determined by physical exploration and that identified by scintigraphy. In fact, in only 1 of 9 cases with positive findings in both diagnostic methods was there partial concordance with regard to the localization of lesions.

Consequently, in the case of dystrophic calcification associated with juvenile dermatomyositis, progressive systemic sclerosis, and CREST, rather than considering dermatologic physical exploration superior to scintigraphy, we conclude that the two diagnostic methods are, in fact, complementary. It is noteworthy that each one has a different usefulness in detecting dystrophic calcification at certain anatomic sites.

In the case of dermatologic exploration, the sites where calcifications are detected most frequently and easily are bony protrusions and soft tissues. Scintigraphy is better in detecting dystrophic calcification in short bones, such as costal arches and vertebral bodies. Therefore, applying both methods jointly, as complementary tools, may enhance the sensitivity and specificity of diagnosis of dystrophic calcification associated with autoimmune diseases of connective tissue, such as juvenile dermatomyositis, progressive systemic sclerosis, and CREST.

This study was conducted with the aid of funds obtained in CONCAYT Sectoral Funds call S0008-2008-1 under application number 87204.

## REFERENCES

- Gutierrez A Jr, Wetter DA. Calcinosis cutis in autoimmune connective tissue diseases. *Dermatol Ther* 2012;25:195-20.
- Walsh JS, Fairley JA. Calcifying disorders of the skin. *J Am Acad Dermatol* 1995;33:693-706.
- Boulman N, Slobodin G, Rozenbaum M, Rosner I. Calcinosis in rheumatic diseases. *Semin Arthritis Rheum* 2005;34:805-12.
- Reiter N, El-Shabrawi L, Leinweber B, Berghold A, Aberer E. Calcinosis cutis: part I. Diagnostic pathway. *J Am Acad Dermatol* 2011;65:1-12.
- Agarwal V, Sachdev A, Dabra AK. Calcinosis in juvenile dermatomyositis. *Radiology* 2007;242:307-11.
- Robertson LP, Marshall RW, Hickling P. Treatment of cutaneous calcinosis in limited systemic sclerosis with minocycline. *Ann Rheum Dis* 2003;62:267-69.
- Chauhan NS, Sharma YP. A child with skin nodules and extensive soft tissue calcification. *Br J Radiol* 2012;85:193-95.
- Nunley JR, Jones LME. Calcinosis cutis. *E Medicine Specialties* 2009;1-18. <http://www.emedicine.com/derm/topic66.html>
- Bowyer SL, Blane CE, Sullivan DB, Cassidy JT. Childhood dermatomyositis: factors predicting functional outcome and development of dystrophic calcification. *J Pediatr* 1983;103:882-88.
- Pachman LM, Abbott K, Sinacore JM, et al. Duration of illness is an important variable for untreated children with juvenile dermatomyositis. *J Pediatr* 2006;148:247-53.
- Blane CE, White SJ, Braunstein EM, Bowyer SL, Sullivan DB. Patterns of calcification in childhood dermatomyositis. *Am J Roentgenol* 1984;142:397-400.
- Fishel B, Diamant S, Papo I, Yaron M. CT assessment of calcinosis in a patient with dermatomyositis. *Clin Rheumatol* 1986;5:242-4.
- Cairolì E, Garra V, Bruzzone MJ, Gambini JP. Extensive calcinosis in juvenile dermatomyositis. *Acta Reumatol Port* 2011;36:180-81
- Palossari K, Vuotila J, Takalo R, et al. Contrast-enhanced dynamic and static MRI correlates with quantitative 99mTc labeled nanocolloid scintigraphy. Study of early rheumatoid arthritis patients. *Rheumatol* 2004;43:1364-73.
- Wu Y, Seto H, Shimizu M. Extensive soft-tissue involvement of dermatomyositis detected by whole-body scintigraphy with 99mTc-MDP and 201Tl-chloride. *Ann Nucl Med* 2006;10:127-30.
- Bar-Server Z, Mukamel M, Harel L, Hardoff R. Scintigraphic evaluation of calcinosis in juvenile dermatomyositis with Tc-99m MDP. *Clin Nucl Med* 2000;25:1013-16.
- Colamussi P, Prandin N, Cittanti C, Feggil L, Giganti M. Scintigraphy in rheumatic diseases. *Best Pract Res Clin Rheumatol* 2004;18:909-26.
- Peller P, Ho V, Kransdorf MJ. Extrasosseus Tc99 MDP uptake: a pathophysiological approach. *Radiographic* 1993;13:715-34